CORNEAL PATHOLOGY

BY: DR. MILLICENT KARIUKI-WANYOIKE

APPLIED ANATOMY

- *The cornea is a clear transparent and elliptical structure with a smooth shining surface.*
- *It consists of 5 layers namely:*
  1. *Stratified squamous epithelium*
  2. *Bowman's membrane*
  3. *Substantia propria or stroma*
  4. *Descemet's membrane*
  5. *Endothelium*

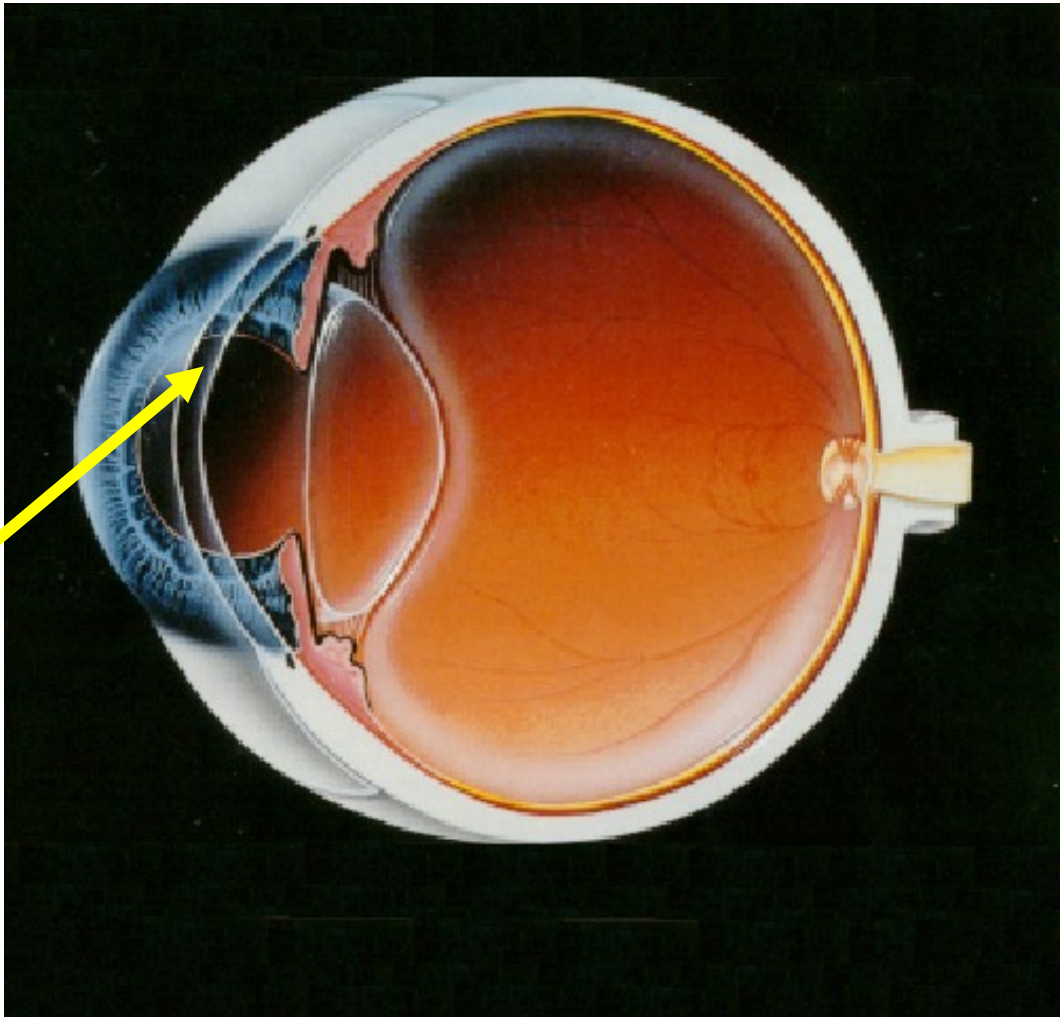

Cornea

LAYERS OF THE CORNEA

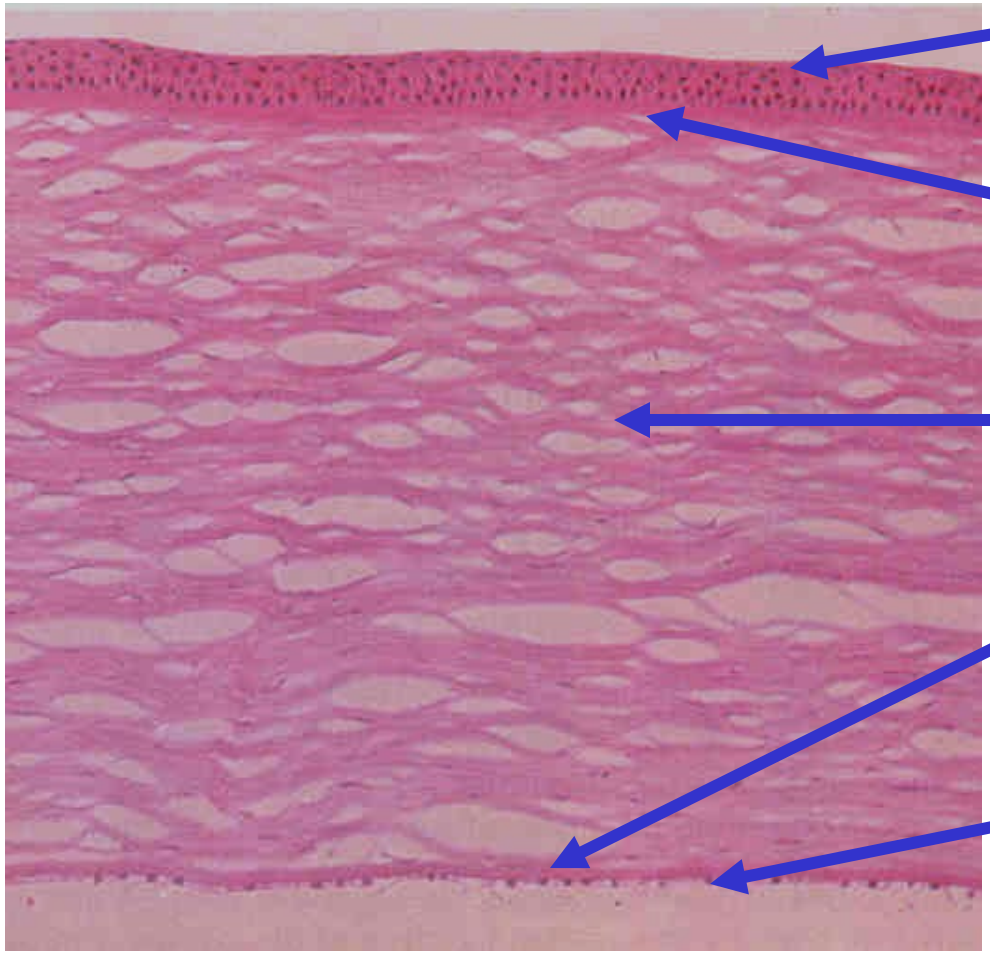

CONT.

- *It is an avascular structure.*
- *It derives nutrition from peri - limbal blood vessels & aqueous humor.*
- *It derives oxygen from atmospheric air through the tear film.*
- *Nerve supply is purely sensory from the ophthalmic division of the 5th cranial nerve through the naso - ciliary branch*

CONT.

Functions

- *Major refracting medium*
- *Protects the intra – ocular contents*

- *This is possible by maintaining corneal transparency by:*
  - *Regular arrangement of corneal lamellae (lattice theory)*
  - *Avascularity*
  - *Relative state of dehydration*

DISEASES OF THE CORNEA

1. INFLAMMATIONS (KERATITIS): SUPERFICIAL & DEEP
2. DEGENERATIONS
3. ECTASIAS
4. PIGMENTATIONS

1. KERATITIS

- *Characterized by:*
  - *Corneal edema, cellular infiltration & associated conjunctival reaction.*
- *Corneal ulcers heal with corneal scars, which lead to blindness*
- *This can be prevented by proper treatment of corneal ulcers*

KERATITIS (CORNEAL ULCER)

- *These include:*

  I. *Bacterial corneal ulcer*

  II. *Hypopyon ulcer*

  III. *Fungal ulcer*

  IV. *Marginal ulcer*

I. BACTERIAL CORNEAL ULCER

- *There is a loss in the continuity of the corneal epithelium associated with tissue infiltration & necrosis*
- *Etiology:*
  - *Gram +ve cocci: S. aureus, S. pneumoniae*
  - *Gram –ve cocci: **N. gonorrhoeae, N. meningitidis***
  - *Gram +ve bacilli: **C. diphtheria***
  - *Gram ive bacilli: P. aeruginosa*
  - *M. tuberculosis, M. leprae*
- *The **highlighted 3 pathogens** above can invade a normal, intact epithelium.*

PREDISPOSING FACTORS

- *Epithelial damage due to trauma e.g. minute FB or misdirected eyelash*
- *Virulent organisms e.g. pneumococcus*
- *Poor resistance:*
  - *Xerosis and keratomalacia (VAD)*
  - *PEM*
  - *Corneal edema → desquamation of epithelium*
  - *Neuroparalytic keratitis e.g. HZO, leprosy*
  - *Exposure of the cornea due to proptosis (7th nerve palsy)*

SYMPTOMS

- *Pain: the cornea has sensory innervation (nasociliary branch of the ophthalmic nerve)*
- *Photophobia (undue sensitivity to light)*
- *Impairment of visual acuity → 2^0 to corneal opacities*
- *Lacrimation → excessive reflex tear production*

SIGNS

- *Blepharospasm esp. in children*
- *Corneal opacification due to infiltration & edema*
- *Ciliary congestion with conjunctival hyperemia (very red eye)*
- *Hypopyon (pus in the AC)*
- *Grey corneal ulcer → bacterial*

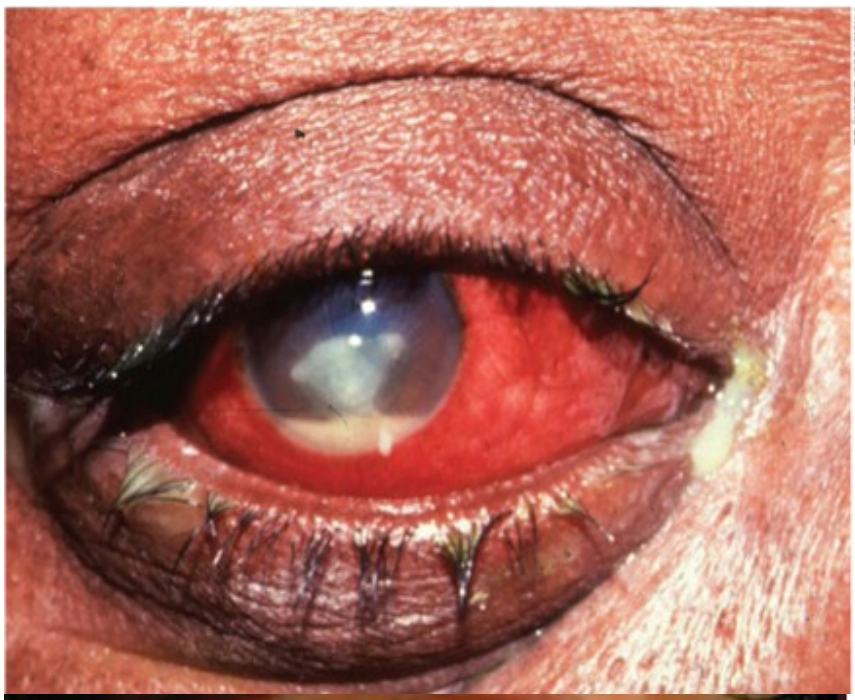

BACTERIAL ULCER WITH HYPOPYON
HYPOPYON.

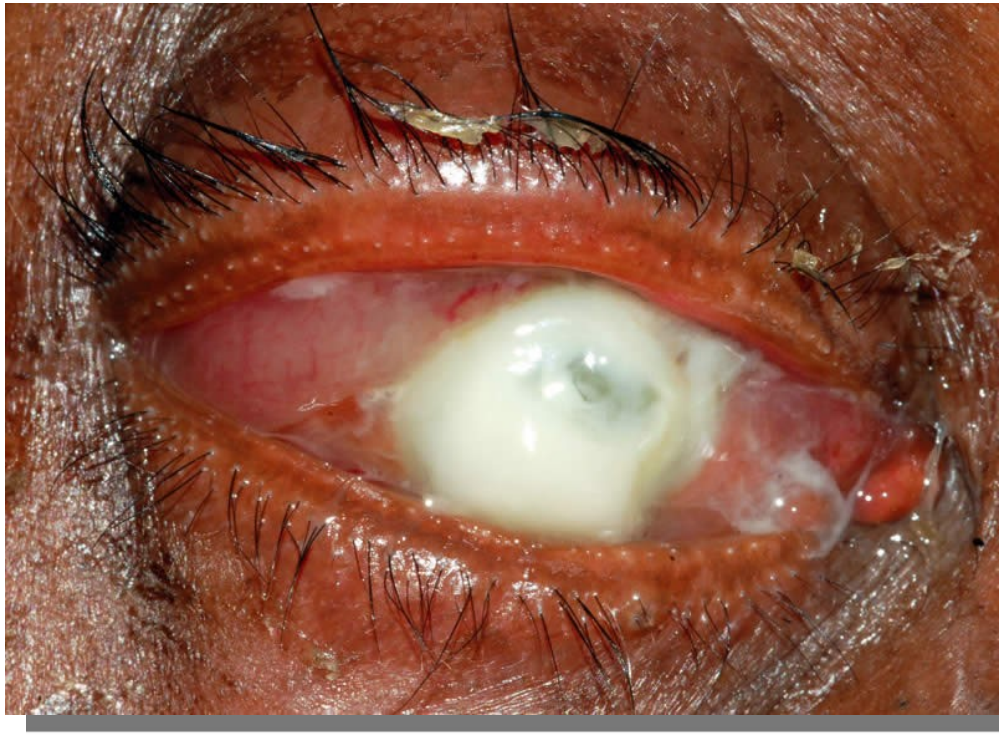

DIAGNOSIS

- *Staining of the cornea by fluorescein stain:*
  - *Superficial staining: Stains the margin of the ulcer brilliant green*
  - *Deep staining: Strains the stromal infiltration defect grass green and the endothelium yellow in color respectively*

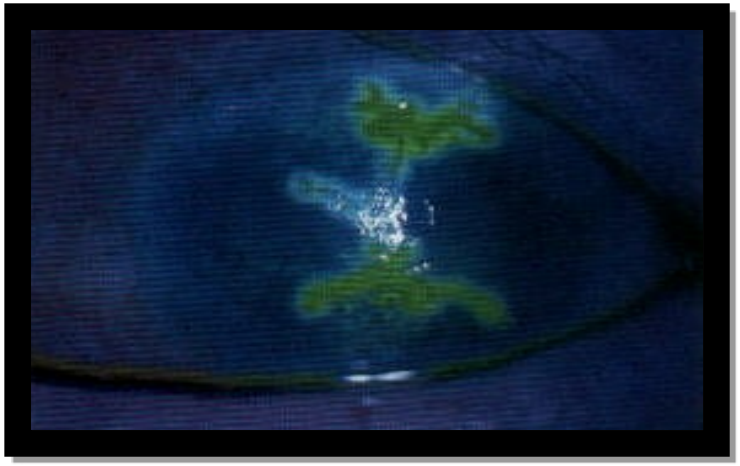

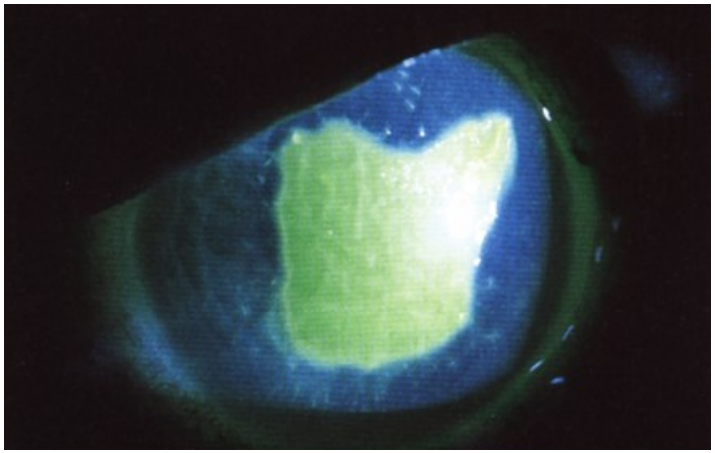

- *Slit lamp examination: irregular margins of the ulcer; also shows details of the anterior segment of the eye*

FLUORESCEIN STAINING

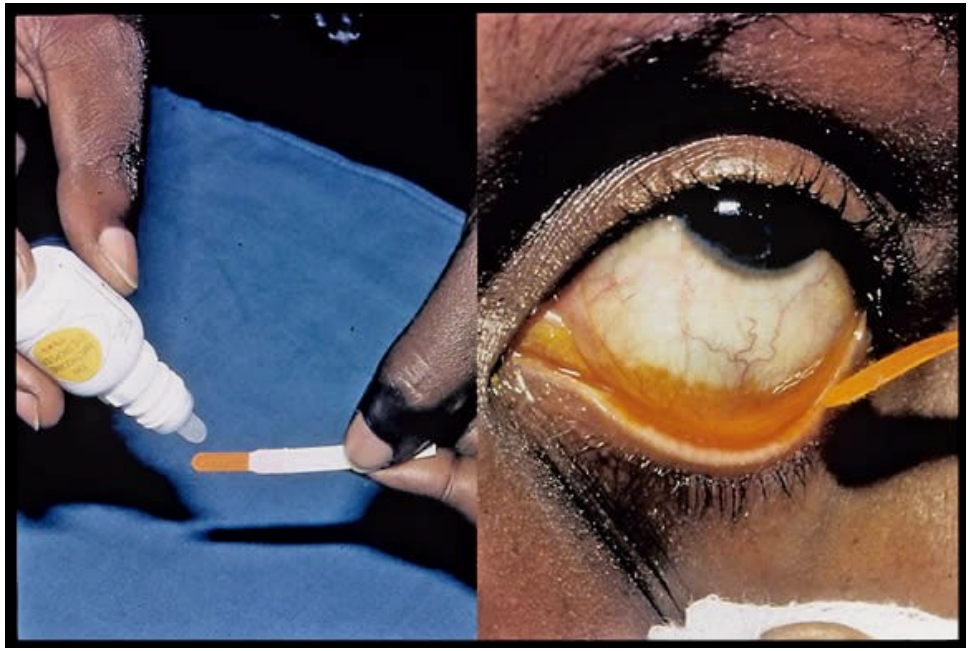

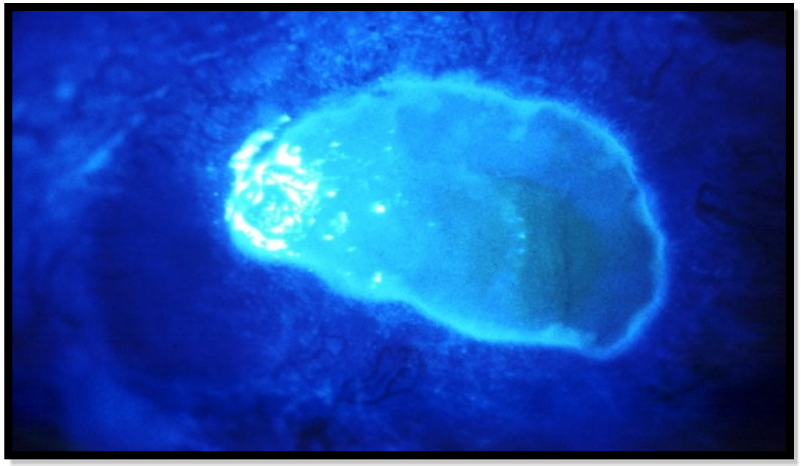

COMPLICATIONS: CORNEAL OPACITY

- *Nebula: corneal scar involves the Bowman's membrane and superficial layers of stroma → slight opacity*
- *Macula: corneal opacity is dense when it involves about half the thickness of the stroma*
- *Leucoma: thick white, dense & totally opaque scar; full thickness of stroma is involved*

OTHER COMPLICATIONS

- *Ectatic cicatrix (Keratectasia): Marked thinning at the site of the ulcer → bulges forwards even in the presence of normal IOP*
- *Descemetocele (Keratocele): herniation of the descemet's membrane; this is seen esp. in infections due to pneumococcus.*
- *Perforation: may occur after sudden strain due to cough, sneeze or spasm of orbicularis muscle*

TREATMENT

- *Control of infection: Initially antibiotic drops every ten minutes for the first 2-3 hours, then hourly and REFER!*
- *Sub - conjunctival antibiotic daily if there is a hypopyon; Gentamicin 20mg under LA.*
- *Cleanliness: irrigate with warm saline (washes away necrotic material, toxin, secretion & pathogenic organisms)*
- *Refer to Ophthalmologist*

CONT.

- *Heat fomentation to prevent stasis and encourage repair of the ulcer*
- *Rest:*
  - *1% atropine to paralyze the ciliary muscles, dilate the pupil & relieve pain*
  - *Pad and bandage to rest the eyeball by restricting its movements*
- *Protection: pad and bandage*
- *Corneal scraping for M/C/S*

II. HYPOPYON ULCER

- *Corneal ulcer associated with sterile hypopyon as a result of iridocyclitis.*
- *The leukocytosis is due to the toxins & not actual bacterial invasion.*
- *It is commonly seen in:*
  - *Old, debilitated, alcoholic, malnourished & immunologically deficient persons.*

CONT.

- *It may occur during or after acute infectious diseases e.g. measles, chicken pox or scarlet fever.*
- *Virulent pyogenic organisms e.g. Pneumococcus may produce hypopyon.*
- *Types:*
  1. *Ulcus serpens*
  2. *Mycotic hypopyon ulcer (keratomycosis, fungal corneal ulcer)*

III. MYCOTIC HYPOPYON ULCER

- *Commonly caused by C. albicans, A. fumigatus etc.*
- *Yeasts frequently affects the immuno - compromised host.*
- *Filamentous fungi (e.g. Aspergillus spp. → MC) are most prevalent in agricultural areas*
- *Incidence:*
  - *Common in rural agricultural areas.*
  - *Usually occurs due to ocular trauma involving vegetable matter*

PREDISPOSING FACTORS

- *Same as for bacterial keratitis*
- *Indiscriminate use of topical or systemic steroids alters host defense.*
- *Occurs commonly in immuno - compromised subjects.*

SIGNS & SYMPTOMS

Symptoms

- *Are the same as for bacterial ulcers but they are less prominent*
- *Mild pain, irritation, watering & presence of yellow patch in the cornea*

Signs

- *Yellow – white colored ulcer with indistinct margins (minimum vascularization)*
- *Dry in appearance with small satellite lesions around the ulcer*
- *Elevated ulcer margin above the surface*
- *Massive hypopyon is present*
- *Slit – lamp exam (SLE$_x$): endothelial plaque*

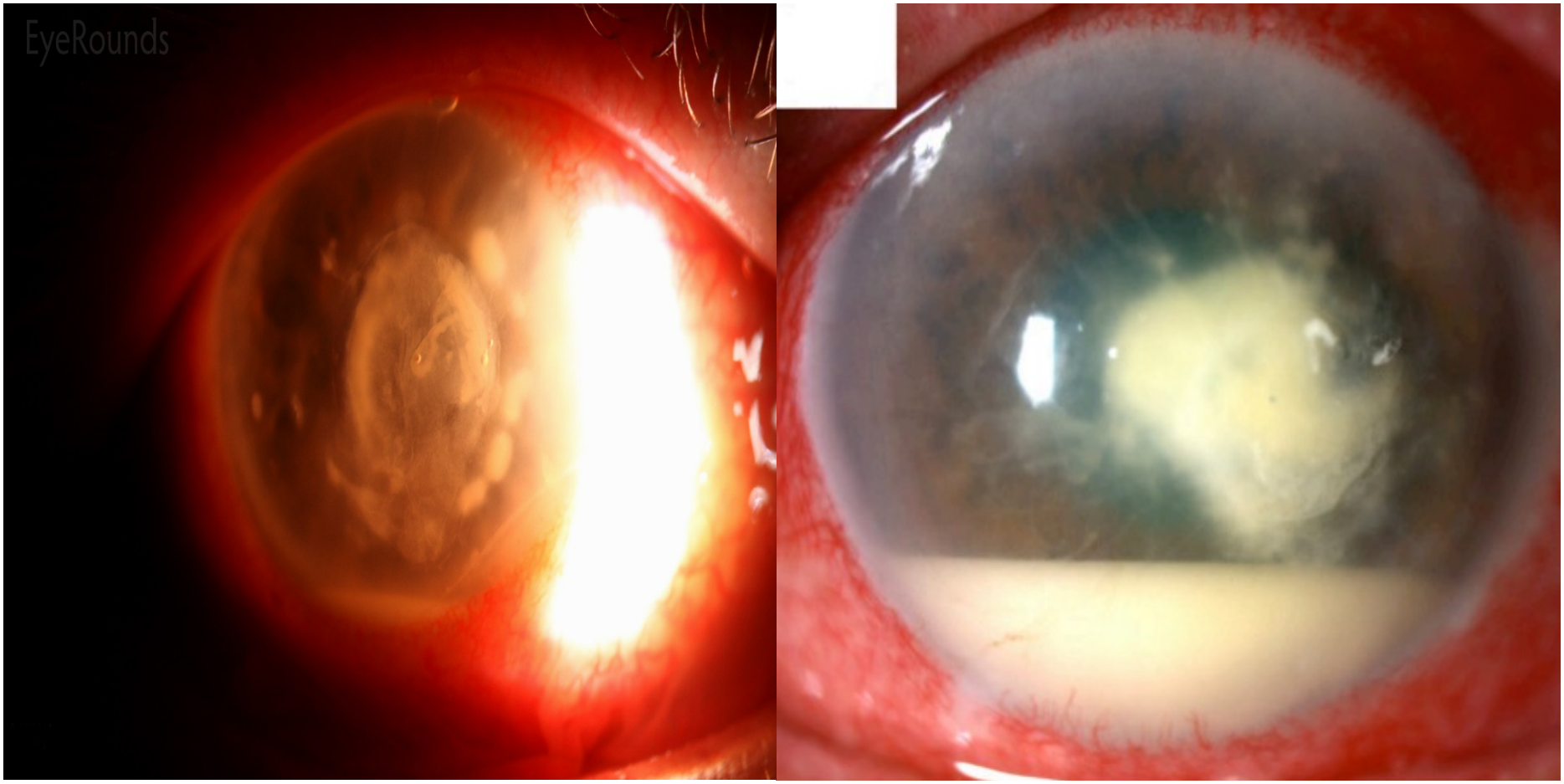
EyeRounds

TREATMENT

- *Treatment takes long → at least 6 weeks*
- *Antifungals:*
  - *Topical or Systemic (if there is intraocular involvement) e.g. Miconazole, Natamycin, Nystatin, Amphotericin-B*
- ***Refer to the Ophthalmologist***
- *Usually admission is necessary in the beginning*

B. SUPERFICIAL NON – PURULENT KERATITIS: (INFECTIOUS CAUSES) HERPES SIMPLEX

- *Caused by herpes simplex virus type I (HSV I)*
- *Presentation of a primary infection is between the age of 6 months and 5 years with unilateral ocular irritation and redness.*
- *Recurrence is due to febrile cold, pneumonia, physical exhaustion or exposure to sunlight.*
- *Symptoms:*
  - *Vesicles on lips, nose, cornea (HSV – I) & genitals (HSV II)*
  - *Great irritation, lacrimation and blepharospasm*

SIGNS

- *Skin lesion: vesicles*
- *Severe, unilateral follicular kerato - conjunctivitis is usually present in children*
- *Blepharitis*
- *Keratitis in 50% of cases*
- *Regional lymphadenitis (pre - auricular LNs)*
- *SLE$_x$:*
  - *Superficial punctate keratitis*
  - *Dendritic ulcer*
  - *Confluent/ geographical ulcer*
  - *Disciform keratitis*

FORMS OF ULCERS



Dendritic ulcer

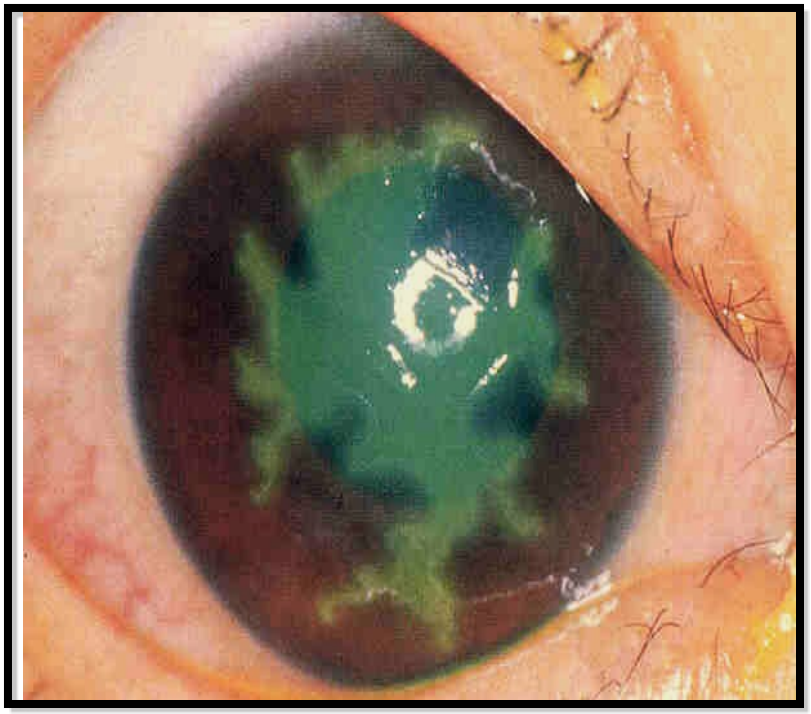

Confluent ulcer/ Geographic or Amoeboid

DIAGNOSIS

- *Immunological tests: Immunofluorescence of epithelial scrapings*
- *Tissue biopsy & culture*

TREATMENT

- *Antiviral drugs: oral acyclovir BD for 7 days*
- *Debridement for dendritic ulcers*
- *Atropine & warm compresses → control iritis*
- *Topical steroids*
  - *Only useful in deep/ disciform keratitis*
  - *They are CI in epithelial lesions. If topical steroids are given to a patient with a dendritic ulcer, the ulcer will enlarge and perforate!!*
- *Full thickness keratoplasty in cases of permanent corneal opacity*

PERFORATION

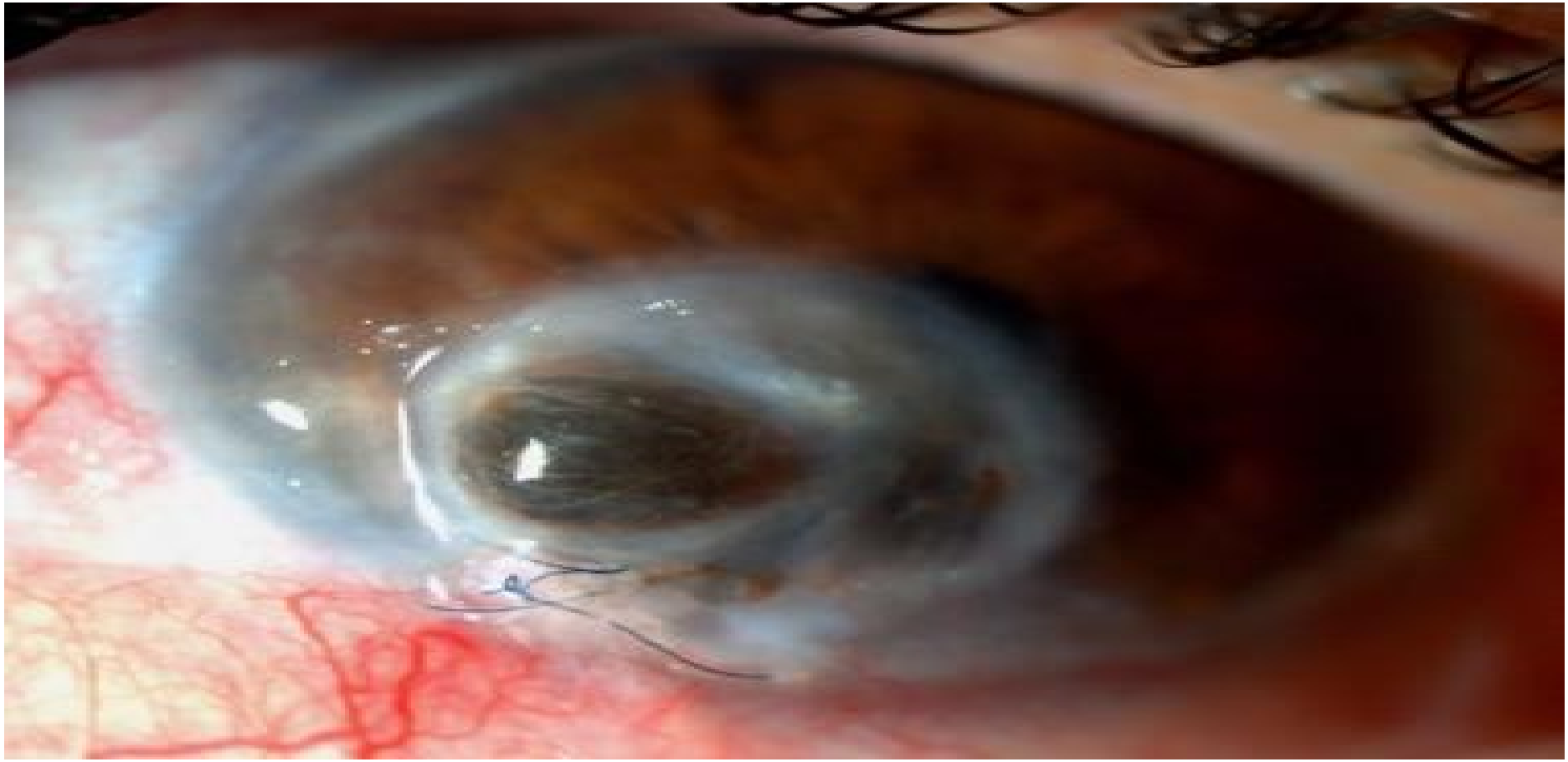

COMPLICATIONS

- *Chronic epithelial ulcer with recurrence*
- *Corneal opacity*
- *Iritis & iridocyclitis*
- *Hypopyon in severe cases*

OPHTHALMICUS (HZO)

- *This is an acute infection of dorsal root ganglion by varicella – zoster virus*
- *It is associated with chickenpox infection in youth or childhood (Endogenous recurrence)*
- *It often occurs in: the elderly with depressed cellular immunity e.g. in DM, alcoholics, malignancy or AIDs*
- *It is always unilateral affecting the gasserian ganglion from where the virus travels down the branches of the ophthalmic nerve.*

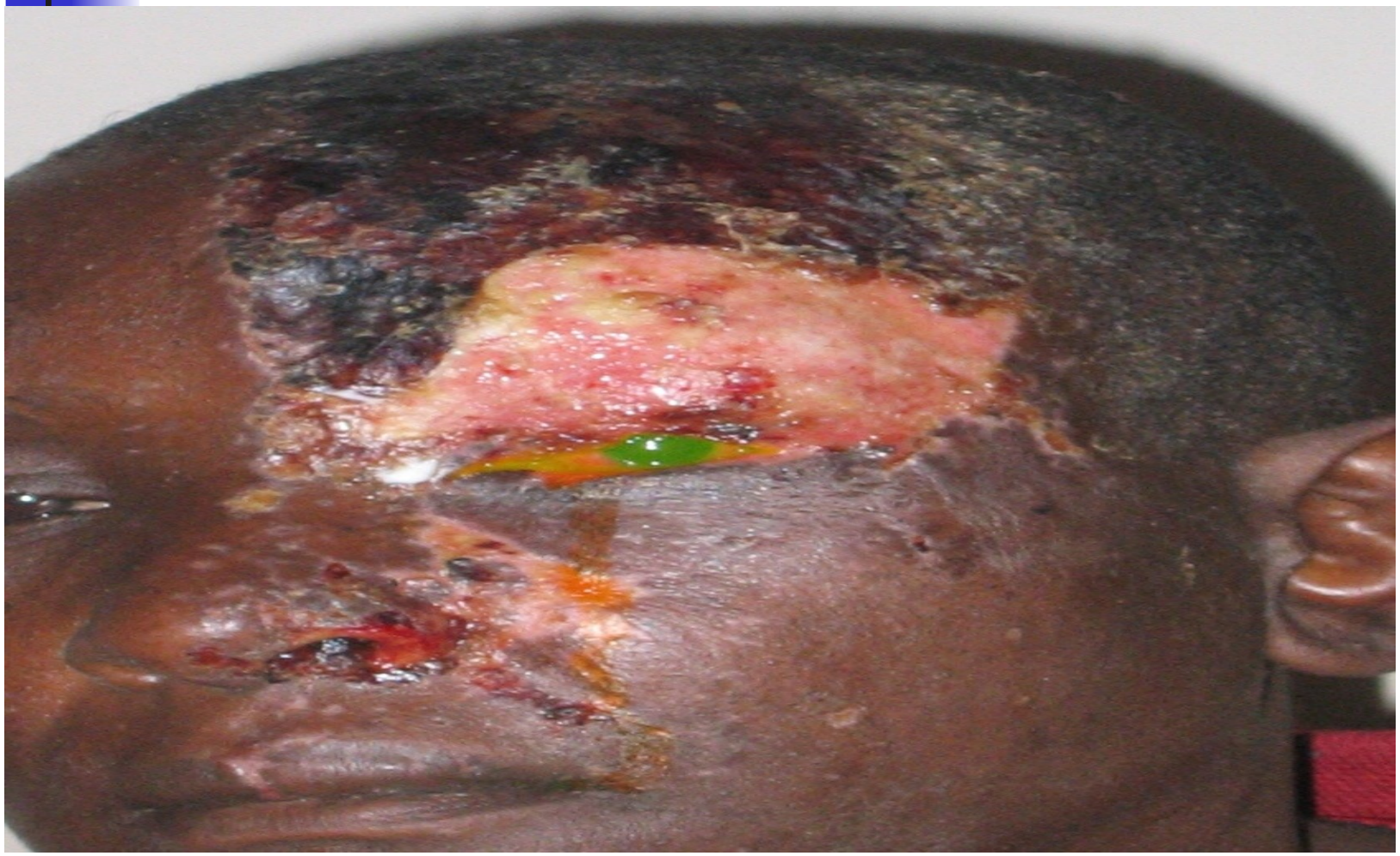

SYMPTOMS

- *Rows of vesicular eruption take place along the branches of the ophthalmic division of the 5th cranial nerve. These suppurate, bleed & cause pitted scarring*
- *Severe neuralgic pain along the course of the nerves is present due to neuritis*
- *Fever & malaise are present at the onset*
- *Skin of lid and face becomes red & edematous*

SIGNS

- *Hutchinson's rule: Ocular involvement associated with eruption of vesicles on the skin of the tip of the nose (nasociliary branch)*
- *Corneal and skin anesthesias are characteristic and persist for a long time*
- *Slit lamp examination: Superficial punctate keratitis (numerous white dots)*

COMPLICATIONS

- *Iridocyclitis & scleritis are associated with disciform keratitis*
- *2° glaucoma*
- *3rd, 6th, 7th cranial nerve palsy and optic neuritis in severe infection*
- *Exposure keratitis*
- *Post – herpetic neuralgia*
- *Acute retinal necrosis*

TREATMENT

- *Acyclovir ointment x 5/day*
- *Systemic Acyclovir: Tabs 800mg 5 times a day x 7 days.*
- *Atropine*
- ***Refer to Ophthalmologist***

ACANTHAMOEBA KERATITIS

- *Saprophytic protozoa*
- *Infections usually occurs in contact lens wearers*
- *Symptoms: Intense pain, photophobia, & lacrimation*

TREATMENT

- *Difficult to diagnose & treat*
- *Penetrating Keratoplasty*
- *Refer to Ophthalmologist*

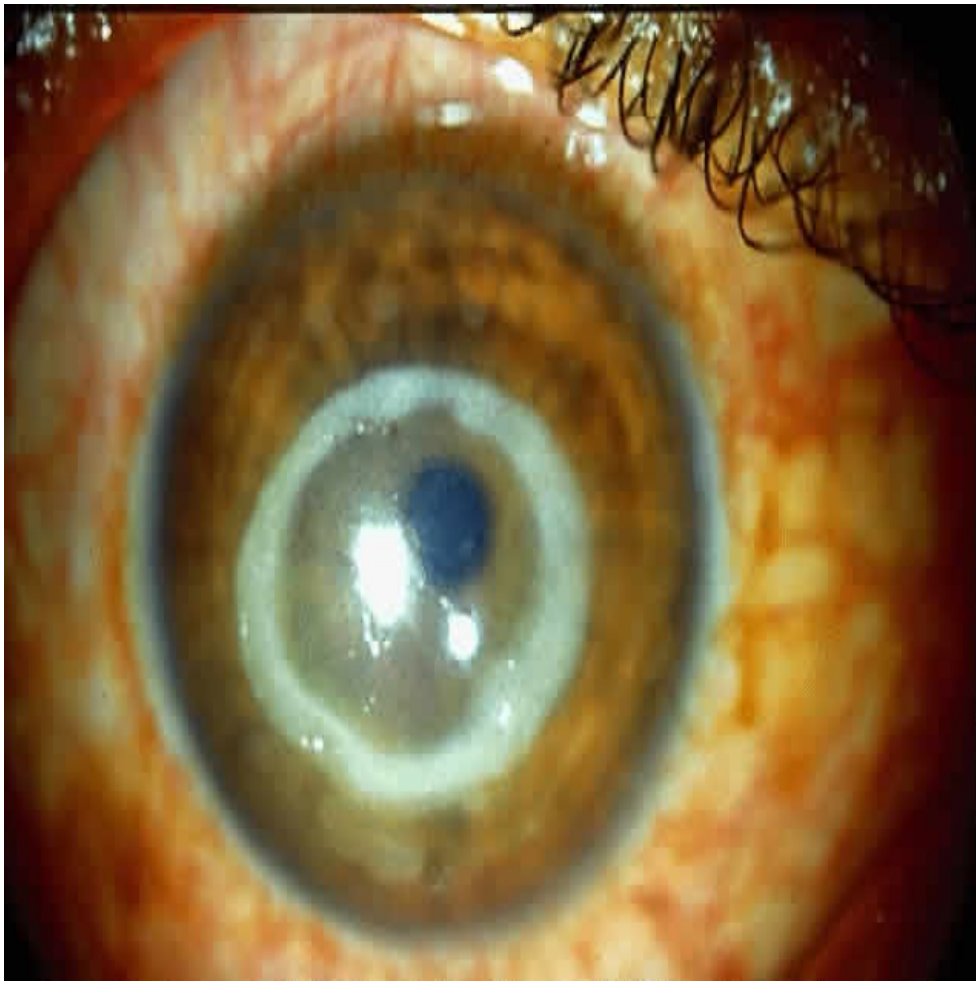

B. SUPERFICIAL NON - PURULENT KERATITIS: (NON - INFECTIOUS CAUSES)

I. *Exposure keratitis*
II. *Traumatic: Chemical burns, Traditional Eye Medicines (TEM)*
III. *Allergic/ Immunological: Mooren's/ Chronic serpiginous/ Rodent ulcer*
IV. *Nutritional: Keratomalacia (VAD)*
V. *Dermatological: Rosacea keratitis*
VI. *Corneal Anesthesia.*

I. EXPOSURE KERATITIS

- *This is keratitis resulting from exposure of the cornea due to insufficient closure of the eye (Lagophthalmos)*
- *Condition is commonly seen in:*
  - *Eyes insufficiently covered by the lids due to paralysis of the orbicularis muscle*
  - *In extreme proptosis e.g. exophthalmos, orbital tumors*
  - *Absence of reflex blinking in extremely ill or comatose patients*

SIGN

- *Corneal erosion with ulcer formation as the epithelium becomes dessicated*
- *There is absence of reflex blinking and defective closure of lids during sleep*

TREATMENT

- *Keep cornea well – covered by applying eye shade & bandage contact lenses (CLs)*
- *Artificial tears, gels and ointments are applied frequently to lubricate the cornea*
- *Strapping the eye at night*
- *Lateral tarsorrhaphy may be done to protect the cornea*
- *Treat the underlying cause of proptosis*

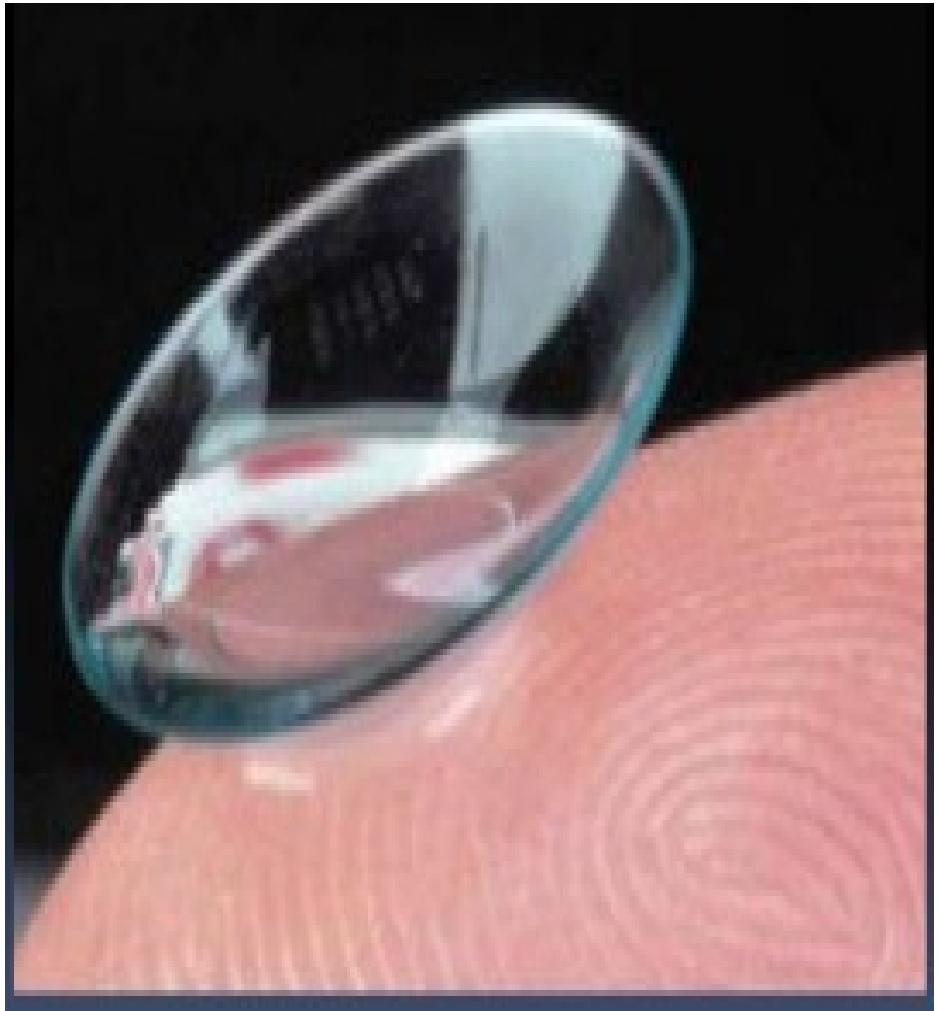

II. TRADITIONAL EYE MEDICINE

- *Harmful TEM may damage the eye by:*
  - *Infection from unsterile preparation*
  - *Delay in presenting to eye clinic*
  - *Chemical burns e.g. acid, alkali*
  - *Physical e.g. heat FB*

WHEN ARE TEM USED?

- *TEMs are used for a great variety of eye diseases. The result of their use is often a more complicated clinical picture because the local remedy may cause further harm to an already abnormal eye.*
- *Measles is one example of a common infective condition causing a red eye where TEM may worsen the clinical picture that corneal ulceration and blindness may follow.*

CONT.

- *In deciding whether the appearance of a child's eye or eyes has been influenced by TEM, the history is important.*
- *Keep in mind the fact that the mother may be very reluctant to admit that TEM has been used. She will realize that the community health worker will generally not approve the use of TEM.*

HOW MAY TEMs AFFECT THE EYE?

- *Traditional healers use a variety of substances in treating the eyes. They may use herbal medicines, the juice of squeezed plant leaves, lime juice, kerosene, toothpaste, breast milk and urine (either animal or human).*
- *Not all substances are harmful, but some may cause a chemical or caustic kerato - conjunctivitis, others may introduce infection, such as bacterial infection with Neisseria gonorrhoeae from human urine, or fungi from plant materials.*

CONT.

- *An unusual appearance of an eye which doesn't seem to have a typical clinical appearance, together with an accurate history, if this is given or admitted, will help make the diagnosis.*
- *Treatment is not easy and depends on the findings. Give topical medication with an antibiotic. As for bacterial ulcers; most of the damage is likely to be due to infection*
- *A child with an eye condition made worse by TEM should be **referred immediately** to the eye specialist.*

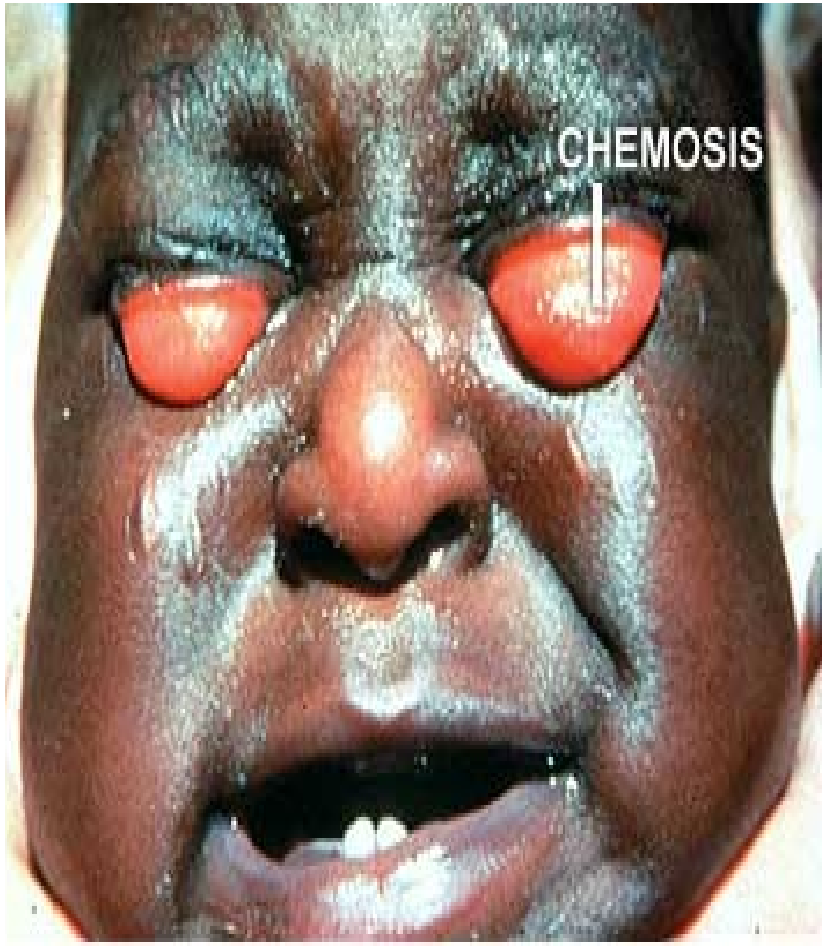

- *The little boy photographed has been treated with a red staining substance, which is made from ground down red rock (stone).*

- *Traditional eye medicines have caused dramatic chemosis (inflammatory swelling of the conjunctiva) of each eye in the child shown top right and one fears for the state of the cornea in each eye*

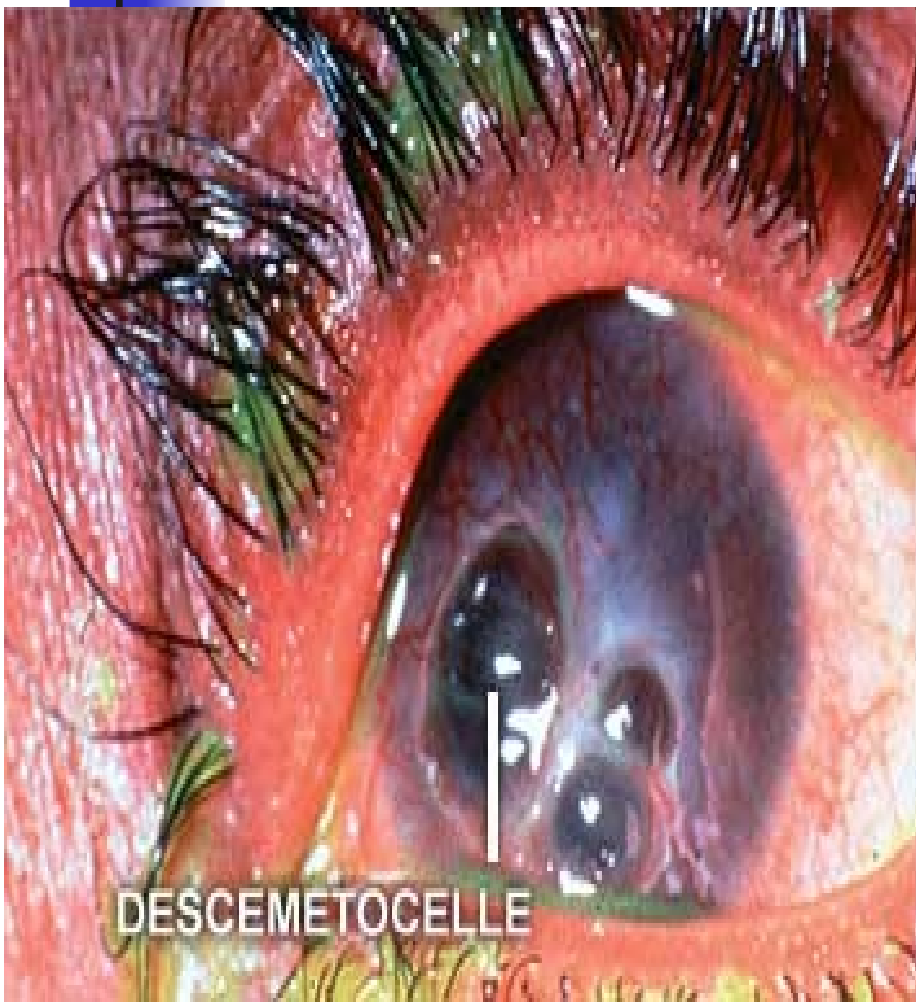

- *The picture bottom left shows a cornea which is thinned and Descemet's membrane, the inner layer of the cornea, is bulging forward (Descemetocele) → there is a real danger of perforation*

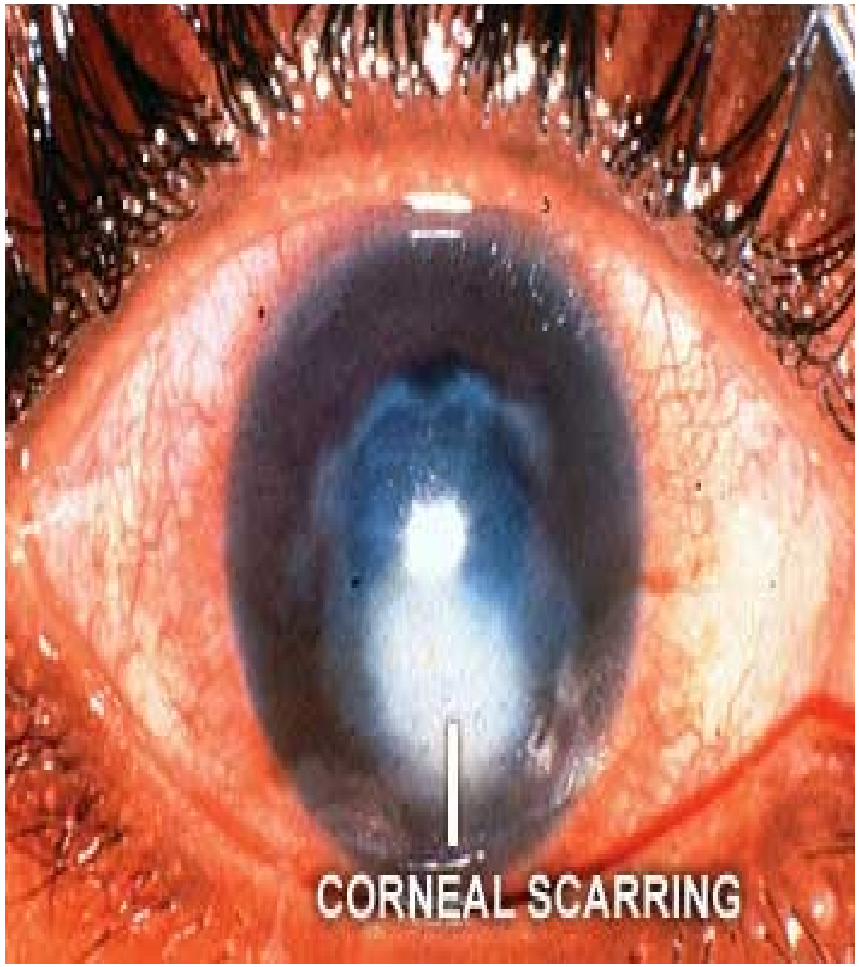

- *In the picture TEMs have contributed to the corneal scarring which may have been present before a traditional form of treatment was used.*

III. MOOREN'S ULCER

- *This is a rare superficial progressive marginal/ peripheral keratitic ulcer i.e. peripheral ulcerative keratitis*
- *It occurs as a result of degenerative process due to corneal ischemia*
- *It starts at the corneal margin and spreads over the whole cornea.*

CONT.

- *Erosion is due to autoimmune lysis of the epithelium.*
- *There are benign & malignant types*
- *It is common in elderly males*
- *Symptoms: severe persistent neuralgic pain with lacrimation*

SIGNS

- *Starts as one or more grey infiltrations which breakdown to form small ulcers that spread centripetally and coalesce with each other*
- *White overhanging edges as the ulcer spreads below the epithelium and superficial layers of the stroma. Resembles the ears of the rabbit (rodent ulcer)*
- *Vascularization at the base of the ulcer.*

COMPLICATIONS

- *Corneal Perforation: rarely perforates but recurrences are common*
- *Corneal Scaring: thin nebular opacity may form over the whole cornea*
- *Blindness*
- *Endophthalmitis*

TREATMENT

- *Difficult because of corneal ischemia (refer to the Ophthalmologist)*
- *Excision of 4 – 6 mm strip of adjacent conjunctiva (source of collagenase and proteoglycanase) +/- cryotherapy)*
- *Immunosuppression e.g. steroids*
- *Prophylactic Antibiotics*
- *Systemic cytotoxic drugs & Surgery may be required*

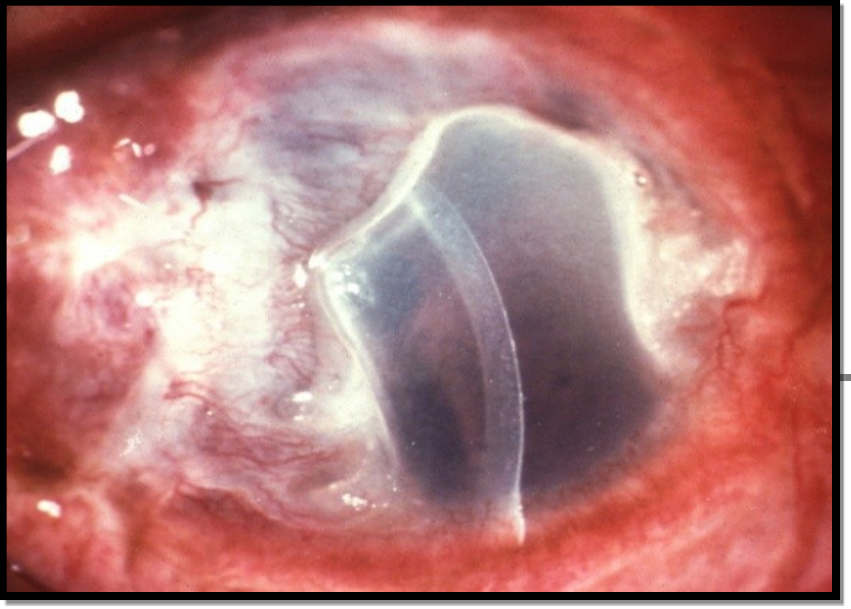

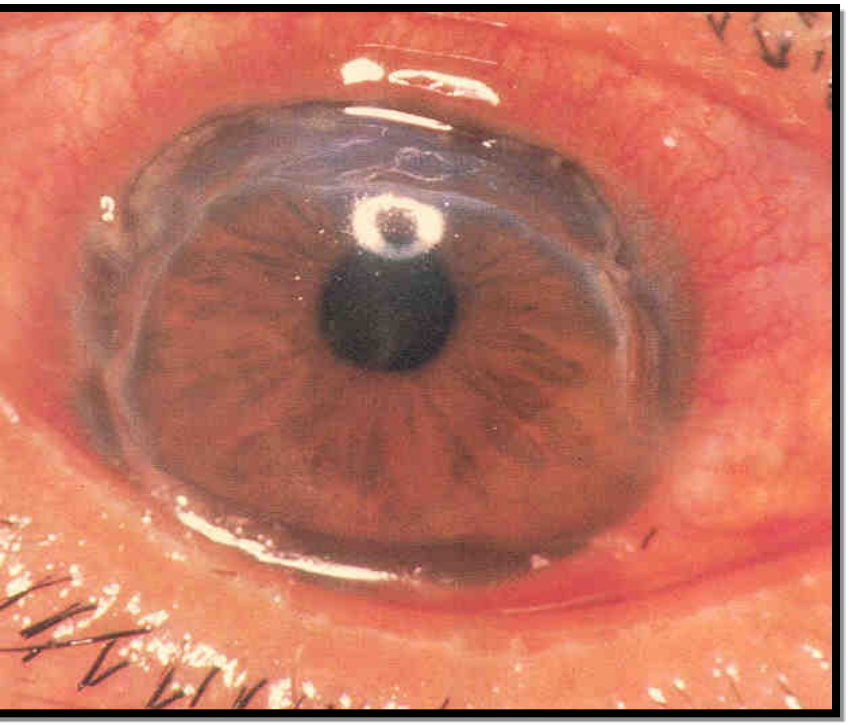

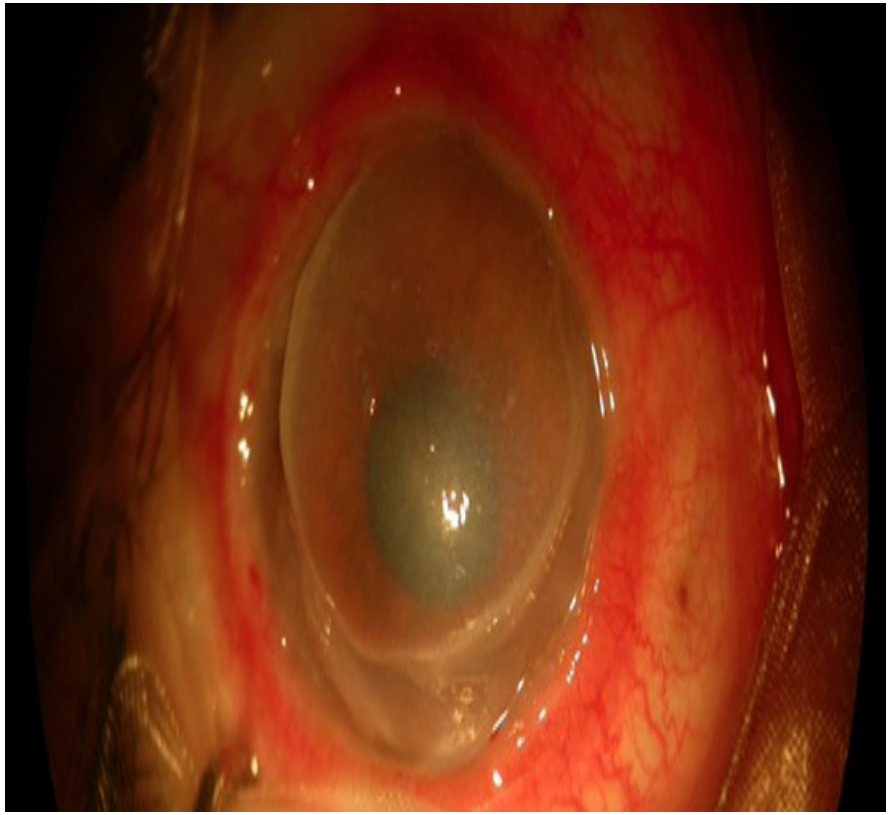

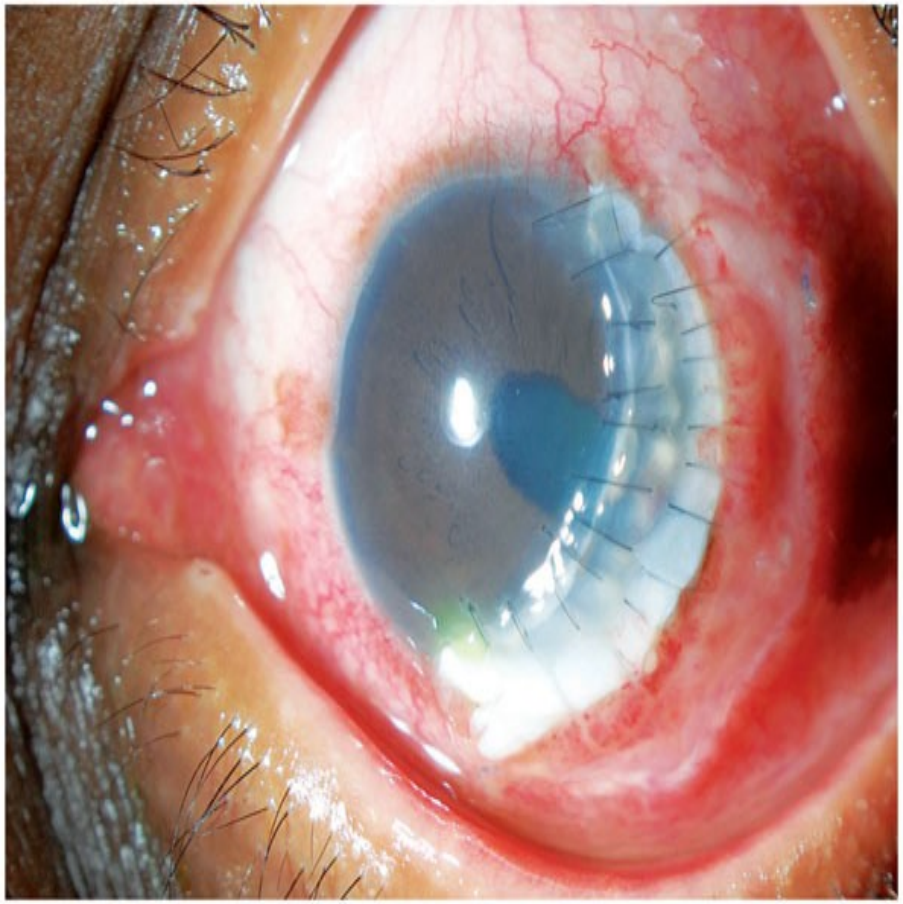

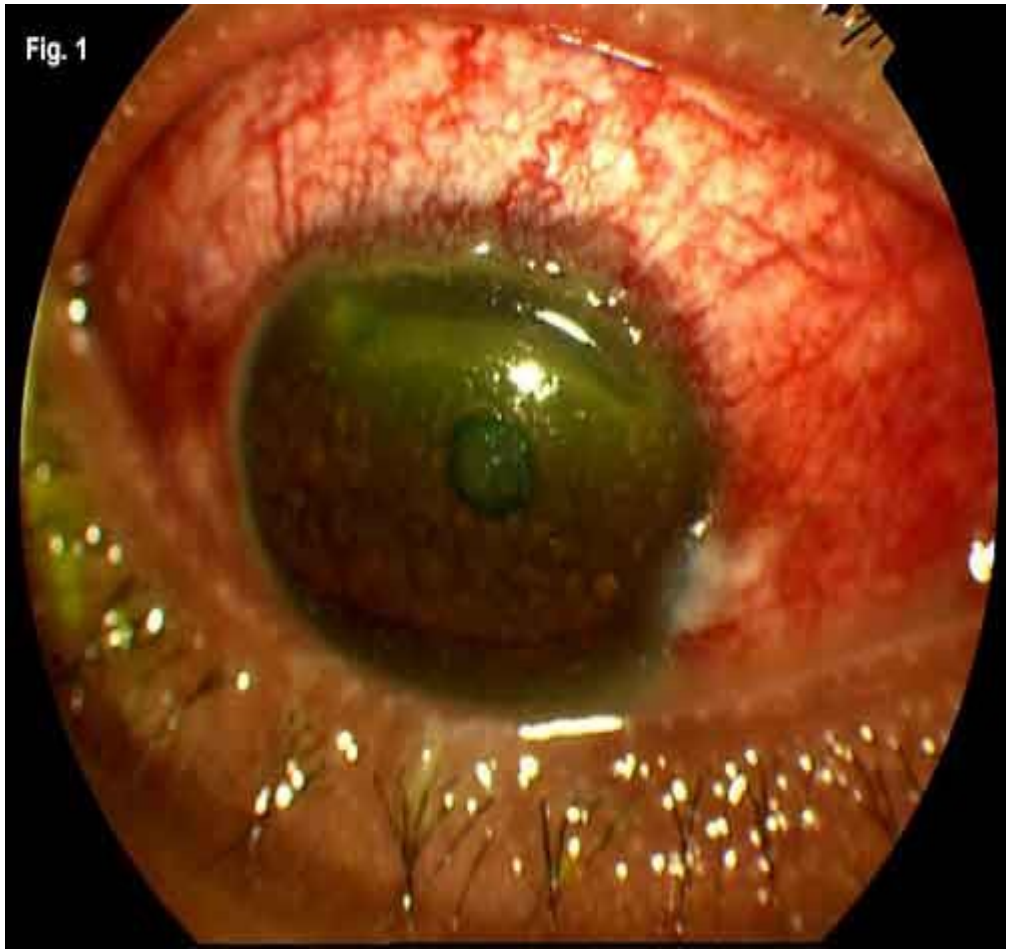
Fig. 1

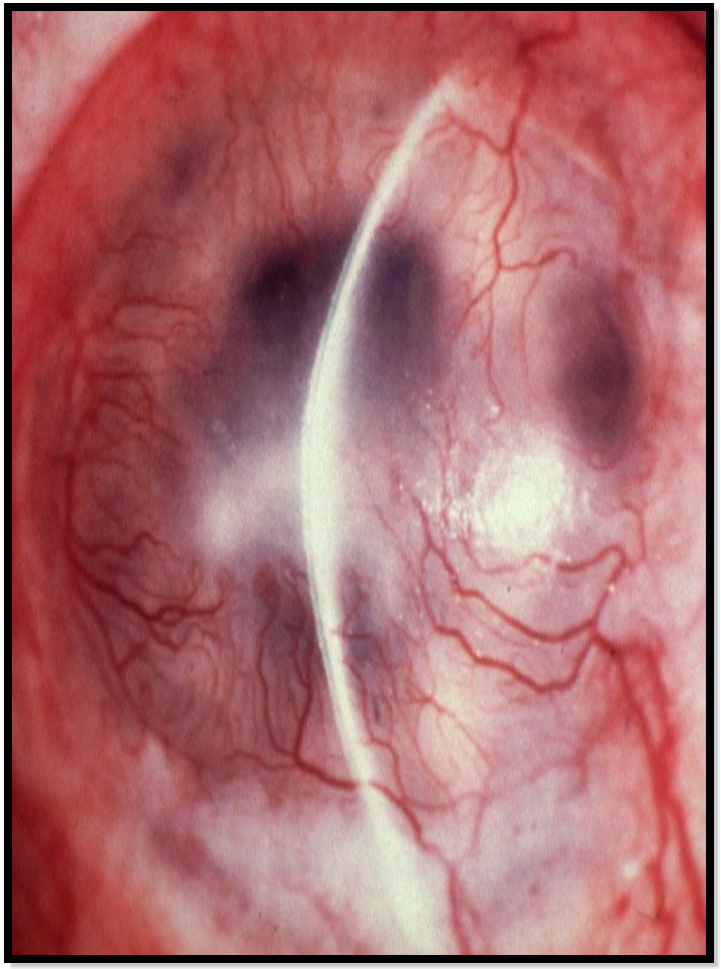

SUMMARY OF TREATMENT OF CORNEAL ULCERS

- *Start Antibiotic drops*
- *Cycloplegic for pain → Atropine*
- *If Viral → start antivirals*
- *If Fungal → Start antifungals*
- *If in doubt → start as above*
- ***Do NOT give steroids***
- ***Do NOT pad the eye***
- ***Refer to Ophthalmologist***

C. DEEP KERATITIS

- *Can result from:*
  - *Corneal abscess*
  - *Congenital syphilis*
  - *Tuberculosis*
  - *Viral (disciform keratitis)*
  - *Sclerosing keratitis*

2. DEGENERATIONS INCLUDE:

- *Arcus senilis*
- *Arcus juvenilis*
- *Bland – shaped keratopathy*
- *Hereditary corneal dystrophy*
- *Reis – Bucklers' dystrophy*
- *Endothelial corneal dystrophy of Fuchs*

3. ECTASIA

- *These can result from:*
  - *Keratoconus*
  - *Keratoglobus*

4. PIGMENTATIONS

- *These can result from:*
  - *Blood staining*
  - *Argyrosis*
  - *Kayser – Fleisher ring*

CORNEAL ANESTHESIA

- *Corneal sensations can be measured using a wisp of cotton. In order to quantitate, one can use an esthesiometer*
- *The innervation density at the center is high and it decreases 5 – fold toward the limbus. This makes the center of the cornea most sensitive.*
- *Corneal sensitivity decreases with age.*

CONDITIONS THAT AFFECT CORNEAL SENSITIVITY:

- *Congenital: congenital trigeminal anesthesia*
- *Acquired:*
  - *DM (reduces)*
  - *Herpes simplex keratitis*
  - *Leprosy*
  - *Adie's tonic pupil*
  - *Myasthenia gravis*
  - *Toxic corneal hypoesthesia*
- *Physiological*
  - *Iris color (the lighter, the more sensitive)*
  - *Gender (M>F)*
  - *Eyelid closure → decreases sensitivity*

MODIFIED BY EFFIE NAILA

END

Worship isn't a feeling you wait for. It's a choice you make.

#JesusIsKing